

# Fibromuscular Dysplasia of the Extracranial Internal Carotid Arteries Associated With an Ulcerative Plaque

BY H. HOOSHMAND, M.D.,\* M. E. BOYKIN, M.D.,† F. S. VINES, M.D.,‡  
AND H. M. LEE, M.D.§

**Abstract:**  
*Fibromuscular Dysplasia of the Extracranial Internal Carotid Arteries Associated With an Ulcerative Plaque*

■ Fibromuscular dysplasia (FMD) of the extracranial internal carotid arteries is a relatively rare angiographical finding which has been reported as an incidental finding during angiography, as well as in association with a variety of different clinical conditions. A case is reported of transient attacks of amaurosis fugax and hemiparesis. Angiography in this patient revealed bilateral FMD of the internal carotids as well as a small ulcerative plaque involving the right internal carotid artery at the region of carotid bifurcation. Surgical treatment directed toward the ulcerative plaque and not the FMD of the carotid arteries has rendered the patient asymptomatic. Lack of symptoms, despite the persistence of FMD, suggests that FMD is of doubtful pathogenic significance.

A small, surgically correctable ulcerative plaque should not be overlooked in the presence of FMD of the internal carotid arteries. The significance of the rare finding of FMD of the internal carotid arteries is not clear.

**ADDITIONAL KEY WORDS** amaurosis fugax transient cerebral ischemia  
anticoagulation carotid endarterectomy

## Introduction

□ Fibromuscular dysplasia (FMD) of the extracranial internal carotid arteries is a relatively rare angiographical finding which has been recognized since 1964.<sup>1-9</sup> It has been reported in association with a variety of clinical conditions, including intracranial aneurysms,<sup>7, 8, 10</sup> intracranial neoplasms,<sup>8, 11</sup> transient cerebral ischemic attacks,<sup>4, 5, 7, 8, 10-12</sup> post-traumatic intracranial disease,<sup>8</sup> asymptomatic<sup>5, 7</sup> and "symptomatic"<sup>5</sup> carotid bruits, headache/migraine,<sup>5, 8</sup> demyelinating disease,<sup>8</sup>

subdural hematoma,<sup>11</sup> epilepsy,<sup>5</sup> arteriovenous malformation,<sup>9</sup> positional cerebral ischemia,<sup>13</sup> cerebral infarction,<sup>3, 8</sup> intracerebral hemorrhage,<sup>8</sup> vertigo,<sup>10, 12</sup> syncope and dizziness,<sup>5, 10</sup> and personality changes.<sup>5</sup> In addition, it has been reported as an incidental finding during radiological evaluation for renal FMD<sup>2, 4, 7</sup> or other conditions.<sup>6, 8</sup> This long list of different clinical conditions has given rise to the question whether there is any direct causal relationship between the FMD and the clinical symptomatology with which it has been reported.<sup>8, 14</sup>

The purpose of this paper is to report a case of FMD of the internal carotid arteries occurring in association with a symptomatic, angiographically demonstrable, and surgically correctable arteriosclerotic ulcerative plaque of the right carotid artery at its bifurcation. Surgical intervention, directed toward the arteriosclerotic lesion and not the FMD, resulted in complete recovery from the frequent attacks of transient cerebral ischemia.

\*Associate Professor of Neurology, †Resident in Neurology, ‡Assistant Professor of Radiology, §Professor of Surgery, from the Division of Neurology and the Departments of Radiology and Surgery, Medical College of Virginia, Virginia Commonwealth University, Richmond, Virginia, 23219.

This study was supported in part by Grant #5T1NB-NSRA.

Reprint requests to Division of Neurology, Medical College of Virginia, Richmond, Virginia (Dr. Hooshmand).

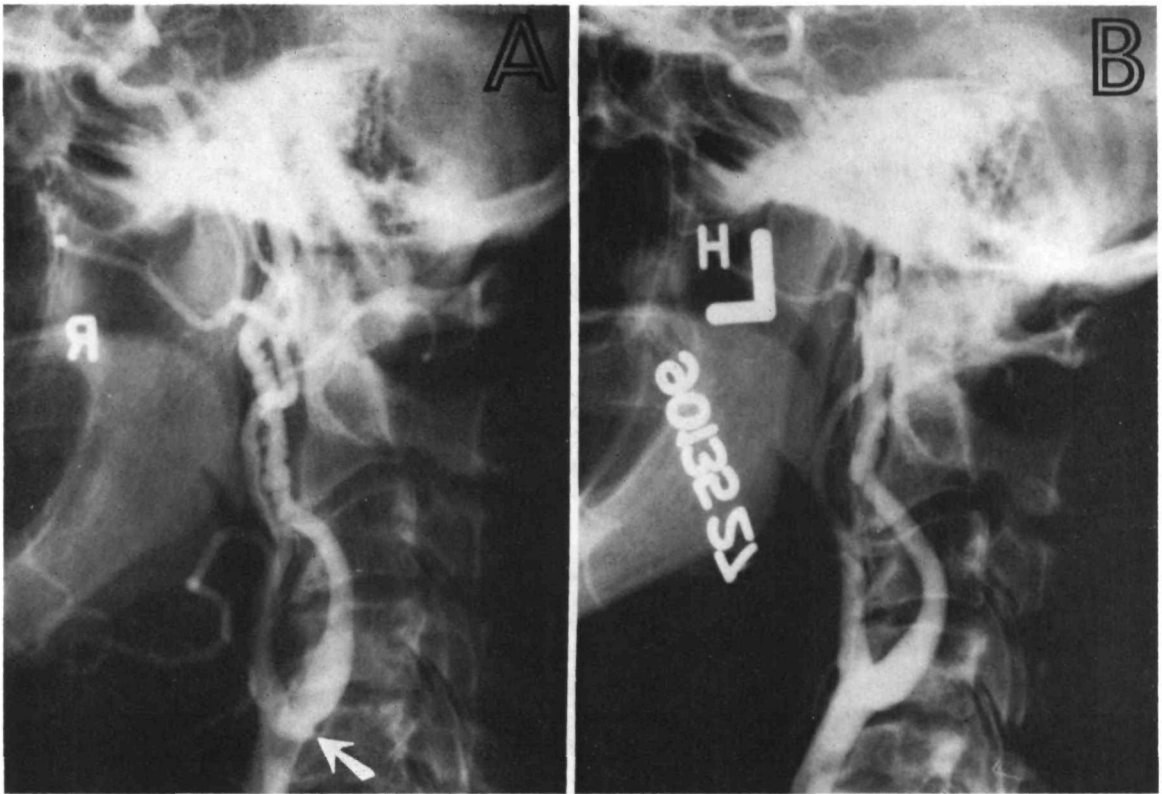


FIGURE 1

*Lateral view of common carotid injections with typical appearance of bilateral fibromuscular dysplasia. (A) Right. (B) Left. The changes spare the proximal 2.5 cm of the internal carotid. Note the ulcerative plaque (arrow) at the common carotid bifurcation on the right.*

## Case Report

A 58-year-old woman was referred to the Medical College of Virginia Hospital with a one-month history of repeated attacks of transient left-sided hemiparesis and hemisensory loss as well as right-sided amaurosis fugax. Physical examination was unremarkable. Blood pressure was 130/80. Neurological examination was normal.

Anticoagulation with heparin was begun at the time of admission. Skull films, EEG, brain scan, and lumbar puncture were all normal.

Bilateral carotid angiography via the femoral approach revealed bilateral FMD of the internal carotid arteries, involvement being much more pronounced on the right (fig. 1). A 2 mm by 2 mm ulcerative plaque of the right carotid artery at its bifurcation was also demonstrated (fig. 1, arrow).

The patient was subsequently anticoagulated with dicumarol in the therapeutic range and dismissed from the hospital. During the next five months there were rare attacks of amaurosis fugax and no episodes of transient hemiparesis.

The patient then suddenly had daily attacks—two to three per day—of amaurosis fugax, frequently associated with transient hemiparesis and hemisensory loss, despite adequate anticoagulation.

Six months after the first hospitalization the patient was readmitted to the hospital. During the first five days of hospitalization dicumarol was discontinued and intravenous heparin, 30,000 units per day, was begun. The patient had no further episodes of amaurosis fugax or transient hemiparesis.

Four-vessel angiography via the femoral approach was performed on day ten of hospitalization, demonstrating again the small ulcerative plaque and the bilateral FMD. No angiographical progression of the FMD was noted when compared with the study done six months before.

The patient underwent right common carotid artery exploration (1/8/71) with the finding of a 2 mm by 2 mm ulcerative plaque at the bifurcation (fig. 2). This was excised and the artery was repaired by patch graft angioplasty. No

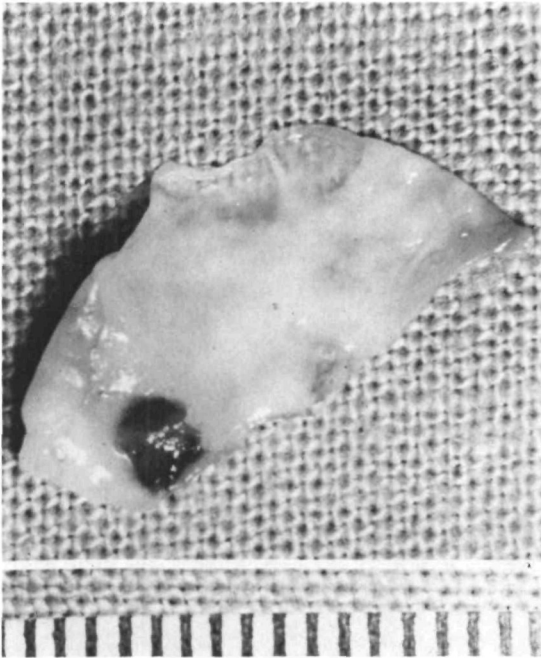


FIGURE 2

*Surgical endarterectomy specimen. Irregular atherosclerotic plaque with a 2 mm ulcer filled with fresh fibrin thrombus. (Scale in mm.)*

attempt was made to surgically approach the FMD.

The patient tolerated the procedure with no evidence of any neurological deficit. She was dismissed from the hospital on no anticoagulants. She has had no further symptoms since surgical treatment.

Four-vessel angiography performed three months after surgery revealed no progression of the FMD and no evidence of the pre-existing ulcerative plaque (fig. 3).

### Discussion

FMD is a nonarteriosclerotic intrinsic arterial disease with a characteristic angiographical appearance.<sup>4, 6, 8</sup> It is to be differentiated from stationary arterial waves, circular spastic contractions, and other abnormalities of the extracranial carotid arteries.<sup>6</sup> The angiographical appearance correlates with the pathological findings of irregular focal areas of hypertrophy of the fibrous and muscular tissue alternating with focal areas of medial thinning and disruption of both internal and external elastic membranes.<sup>2, 5, 9, 15</sup>

The incidence of FMD of the internal

carotid arteries in the general population is unknown, but it is uncommon.<sup>8, 12</sup>

The natural history of FMD of the carotid arteries is not clear. In one case report, there was no progression of the FMD over six months' follow-up.<sup>14</sup> In another case report, the disease developed bilaterally in the patient after an initial study three months earlier had demonstrated unilateral involvement.<sup>11</sup> In our case, we noted no progression of FMD of the internal carotid arteries six months and nine months following the initial angiographical study.

It has been emphasized that the proximal 2.5 cm of the internal carotid artery is usually spared from FMD.<sup>6, 8</sup> In our case, the ulcerative plaque was proximal to the area involved with FMD, but isolated to the carotid artery bifurcation. The ulcer was in the base of an irregular plaque which differentiated it from

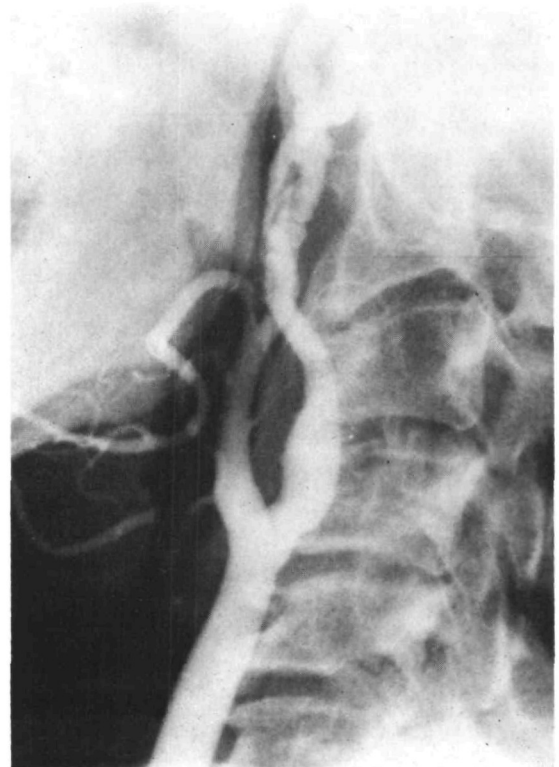


FIGURE 3

*Lateral view of right common carotid injection three months postoperatively. Intimal defect anteriorly in the internal carotid is the site of the temporary surgical shunt.*

a single mural aneurysm. On the first admission of the patient to the hospital, the ulcerative plaque was considered clinically insignificant when compared to the degree and severity of FMD. Eventually, however, the removal of the ulcerative plaque rendered the patient asymptomatic despite no treatment for the bilateral FMD of the internal carotid arteries. Morris et al.,<sup>10</sup> Ehrenfeld et al.,<sup>4</sup> and Polin<sup>12</sup> have reported cases of FMD of the internal carotid arteries in association with arteriosclerotic disease at the carotid bifurcation. This combination was discovered either angiographically or at the time of surgery, necessitating endarterectomy and patch graft angioplasty. However, the surgical treatment in these case reports had been originally aimed at FMD. In our case, no attempt was made to correct the FMD, and the patient became asymptomatic after removal of the ulcerative plaque.

Surgical treatment has not been accepted as a reasonable approach to FMD of the carotid arteries.<sup>8, 14</sup> The indications for surgery are vague, and no one surgical procedure has been consistently advocated.<sup>3, 10, 11, 16</sup> On the other hand stereotyped transient cerebral ischemia has been frequently reported in case reports of FMD in which carotid arteriosclerotic plaques or stenoses were simultaneously present.<sup>3, 4, 10, 11, 17</sup> Since FMD may coexist with the more commonly occurring arteriosclerotic carotid artery disease, it would seem advisable to pursue the patients with FMD who have transient cerebral ischemia for evidence of a surgically amenable arteriosclerotic lesion if they can tolerate the surgical procedure otherwise. A known indication for carotid endarterectomy is the clinical picture of amaurosis fugax, transient neurological signs, and angiographically proved ulcerative plaque.<sup>17</sup> This should not be overlooked or disregarded because of the coexisting FMD which may not be responsible for the patient's symptoms despite its striking appearance on angiography.

## References

1. Palubinskas AJ, Ripley HR: Fibromuscular hyperplasia in extrarenal arteries. *Radiology* **82**:451-495, 1964
2. Palubinskas AJ, Perloff D, Newton TH: Fibromuscular hyperplasia: An arterial dysplasia of increasing clinical importance. *Amer J Roentgen* **98**: 907-913, 1966
3. Connett MD, Lausche JM: Fibromuscular hyperplasia of the internal carotid artery: Report of a case. *Ann Surg* **162**: 59-62, 1965
4. Ehrenfeld WK, Stoney RJ, Wylie EJ: Fibromuscular hyperplasia of the internal carotid artery. *Arch Surg* **95**: 284-287, 1967
5. Harrison EG, McCormack LJ: Pathologic classification of renal arterial disease in renovascular hypertension. *Mayo Clin Proc* **46**: 161-167, 1971
6. Houser OW, Bakes HI: Fibromuscular dysplasia and other uncommon diseases of the cervical carotid artery: Angiographic aspects. *Amer J Roentgen* **104**: 201-212, 1968
7. Wylie EJ, Binkley FM, Palubinskas AJ: Extrarenal fibromuscular hyperplasia. *Amer J Surg* **112**: 149-155, 1966
8. Sandok BA, Houser OW, Baker HL, et al: Fibromuscular dysplasia: Neurologic disorders associated with disease involving the great vessels in the neck. *Arch Neurol* **24**: 462-466, 1971
9. Rothfield NJH: Fibromuscular arterial disease: Experimental studies. *Australasian Radiol* **14**: 294-297, 1970
10. Bergan JJ, MacDonald JR: Recognition of cerebrovascular fibromuscular hyperplasia. *Arch Surg* **98**: 332-335, 1969
11. Galligioni F, Iraci G, Marin G: Fibromuscular hyperplasia of the extracranial internal carotid artery. *J Neurosurg* **34**: 647-651, 1971
12. Polin SG: Carotid artery fibromuscular hyperplasia: Three cases and a review of the literature. *Amer Surg* **35**: 501-504, 1969
13. Rainer WG, Cramer GG, Newby JP, et al: Fibromuscular hyperplasia of the carotid artery causing positional cerebral ischemia. *Ann Surg* **167**:444-446, 1968
14. Kaufman HH: Fibromuscular hyperplasia of the carotid artery: In a case associated with an arteriovenous malformation. *Arch Neurol* **22**: 299-304, 1970
15. Wylie EJ, Wellington JS: Hypertension caused by fibromuscular hyperplasia of the renal arteries. *Amer J Surg* **100**: 183-193, 1960
16. Morris GC, Lechter A, DeBaKey ME: Surgical treatment of fibromuscular disease of the carotid arteries. *Arch Surg* **96**: 636-643, 1968
17. Fields WS, Maslenikov V, Meyer JS, et al: Joint study of extracranial arterial occlusion. V. Progress report of prognosis in operated and nonoperated patients with transient cerebral ischemic attacks and cervical carotid artery lesions. *JAMA* **211**: 1993-2003, 1970