

Original Article

Is Thermal Imaging of Use in Pain Management?

H. Hooshmand, M.D.

Neurological Associates Pain Management Center, Vero Beach, Florida, USA

Infrared thermal imaging has been used in medicine for diagnosis of conditions such as peripheral and central vascular disease and breast cancer, and a variety of painful conditions such as neuropathic pain and nerve root disorders. The following text addresses the role of thermal imaging in the diagnosis and management of pain. Infrared thermography cannot be exclusively diagnostic of a specific disease, but provides important diagnostic information only limited to the thermal function of the sympathetic system. As such, it can be used as both a diagnostic tool and a guide in application of treatment modalities. The following is a review of its applications in the management of chronic pain.

Methods

Infrared thermal imaging was studied on 100 control volunteers and 682 neuropathic pain patients. A Bales Scientific Thermal Processor (Bales Scientific, Walnut Creek, CA) and Agema Cameras (Flir) were used. The results were correlated with the clinical diagnosis. A temperature asymmetry of over 1° C was considered abnormal.

Results

The control group showed abnormal infrared thermal imaging in 14 (14%) of volunteers. Twelve were found to be due to healed, old injuries 6 to 43 yrs earlier. The 682 neuropathic pain patients showed accurate clinical correlation in 78%, bilateral abnormalities in 36%, remote (referred pain abnormalities) in 43%, and unrelated abnormalities due to asymptomatic old injuries or herpes in 9%. Neuropathic pain has a tendency for spread (referred pain), and causes inflammation [1]. It covers a large spectrum of illnesses that disturb the vasomotor function (Table 1).

Discussion

Whereas somatic large myelinated nerve dysfunction due to trauma, disc herniation, malignancy, etc., can be studied with tests such as magnetic resonance imaging (MRI), computed tomography (CT) scan, or electromyographic nerve conduc-

tion velocity studies, the neuropathic pain originating from unmyelinated perivascular sympathetic small C fibers (thermoreceptors) is too small to be represented on electromyographic nerve conduction velocity studies, MRI, or CT. Pain of this type is best evaluated with infrared thermal imaging. Trying to diagnose neuropathic pain with electromyographic nerve conduction velocity studies is similar to trying to diagnose viral infections with a regular microscope instead of an electron microscope. Infrared thermal imaging, by virtue of its hypersensitivity, may yield confusing results due to asymptomatic old injuries, and due to the complexity of sympathetic physiology.

Whereas the original nerve insult may be focal, it can affect the dermatomal, and regional (e.g., entire extremity) temperature surrounding the pathologic area. Usually, the apex (Fig. 1) of the lesion is identified as a hyperthermic area due to paralysis of the sympathetic nerve fibers. The apex is surrounded by a dermatomal (Fig. 2) and regional hypothermia. The regional spread of the thermal response is achieved by wide dynamic range of spread of the impulse in the spinal cord, as well as the spread of the impulse horizontally and vertically through the chain of sympathetic ganglia present on each side of the vertebral column (Fig. 3). The same two anatomical factors result in regional, vertical, and horizontal spread of the temperature changes. This results in spread of the pain and temperature changes to ipsilateral and contralateral remote areas. Simple immersion of the right hand in ice-cold water results in hypothermia in the opposite hand as well as the right foot and right side of the face. In chronic pathologic states, the thermal dysfunction may become permanent and may spread to the contralateral extremity as well.

Factors influencing hyperthermia and hypothermia: Hyperthermia is the result of (1) damage to the nerve resulting in paralysis of the vasoconstrictive function, and (2) neural blockage of α -receptors (sympathetic nerve block) with secondary vasodilation.

Hypothermia is secondary to (1) hyperactivity of sympathetic efferent nerve fibers causing vasoconstriction, and (2) increased sensitivity of the α -receptors such as is seen with prolonged denervation. This phenomenon of denervation hypersensitivity explains the reason for the therapeutic failure of sympathectomy. A sympathectomized arteriole at

Table 1. Etiology of neuropathic pain

Diabetic neuropathy
Vascular disease
Infectious neuropathy
Traumatic neuropathy
Nerve root injury
Entrapment neuropathy
Repetitive stress injury
Phantom pain
Sympathetically mediated pain
Reflex sympathetic dystrophy (CRPS I and II)
Disimmune neuropathy

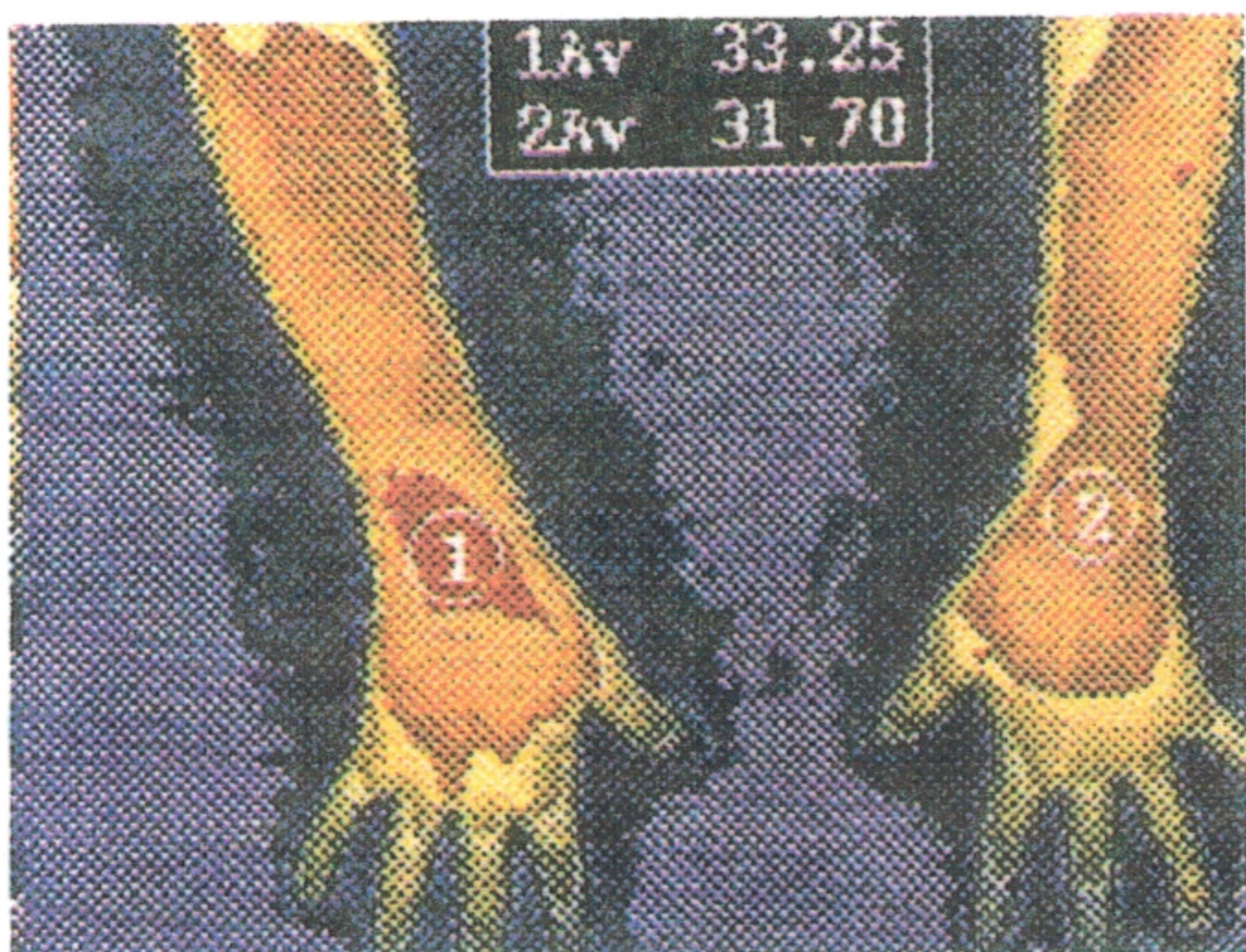


Fig. 1. The apex of the area of permanent sympathetic nerve damage (1) results in leakage of heat in the absence of normal sympathetic vasoconstriction.

first undergoes vasodilation. After several weeks or months, the nerves around the arteriole become hypersensitive and are stimulated by the slightest increase in circulatory or topical norepinephrine level, resulting in denervation hypersensitivity and cold extremity. The beneficial effect of sympathectomy lasts only from a few months to a maximum 1 to 2 yrs.

Anatomy

There are two types of nociceptive pain fibers: (1) the somatic, circumscribed, quite focalized pain that may originate from the central or peripheral nervous system and usually terminates in the postcentral parietal cortex on the opposite cerebral hemisphere; and (2) the neuropathic sympathetic pain that is more of a regional, less-circumscribed type of pain mainly in a thermatomal distribution (arteries and arterioles) (Fig. 2).

The “neuropathic pain” is characterized by the involvement of the sympathetic vasomotor system. The neuropathic sensory (afferent) portion of the sympathetic reflex arc consists of a primitive sensory system that is not well defined and can generate unpleasant visceral and neuropathic pain. The pain is perceived as involving regions of the body such as the upper or lower extremity. In contrast to somatic sen-

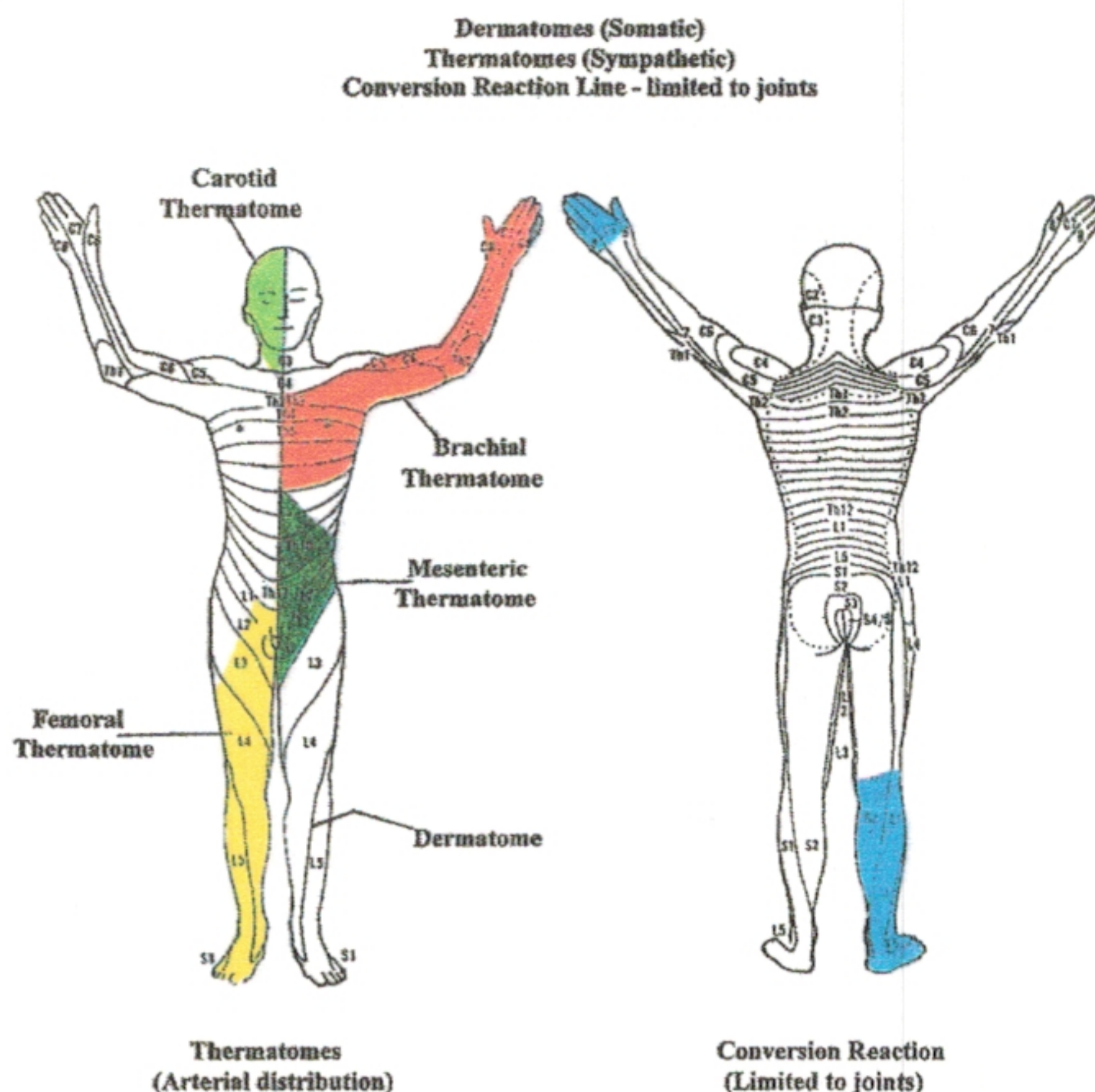


Fig. 2. In reflex sympathetic dystrophy the sensory loss is usually in the thermatomal distribution of the blood vessels rather than in the nerve root distribution of the somatic nerves (dermatomes). The malingering sensory loss is usually limited to the joints (right).

sory pain, sympathetic sensory pain has a tendency to spread, and to generate referred pain (especially to paraspinal regions). Whereas somatic sensory pain is felt in the distribution of the nerve roots (dermatomal radiculopathy), the sympathetic nerves have a tendency to follow the arteries (for control of body temperature) and to follow the small arterial branches of arterioles, resulting in a thermatomal distribution of the pain (Fig. 2). The pain has a hyperpathic and allodynic characteristic: the hyperpathia pain is regional, with a tendency to perpetuate and to spread; allodynia refers to the fact that normally nonpainful stimuli (such as touch or a breeze) reproduce the severe and intense pain and elicit a severe, painful response. The somatic nervous system provides a variety of sensory modalities including fine touch, vibration, position sense, and well-defined circumscribed pain. The sensory input terminates in the postcentral parietal sensory cortex of the brain, where it is perceived and modulated as a conscious, clear-cut, focalized, well-defined sensation. In contrast, the neuropathic pain fibers terminate in the temporofrontal (limbic system) lobes [2], causing alarm, agitation, and depression [3,4].

Physiology

The sympathetic nervous system has three main functions:

1. Protection of the internal environment of the body; example: control of body temperature.
2. Control of vital signs (BP, pulse, and respiration). Sympathetic stimulation results in cold skin (temperature preservation), increased heat and circulation in the muscle and bone, and elevation of pulse and BP, which make the hyperpathic response an objective evidence of pain.

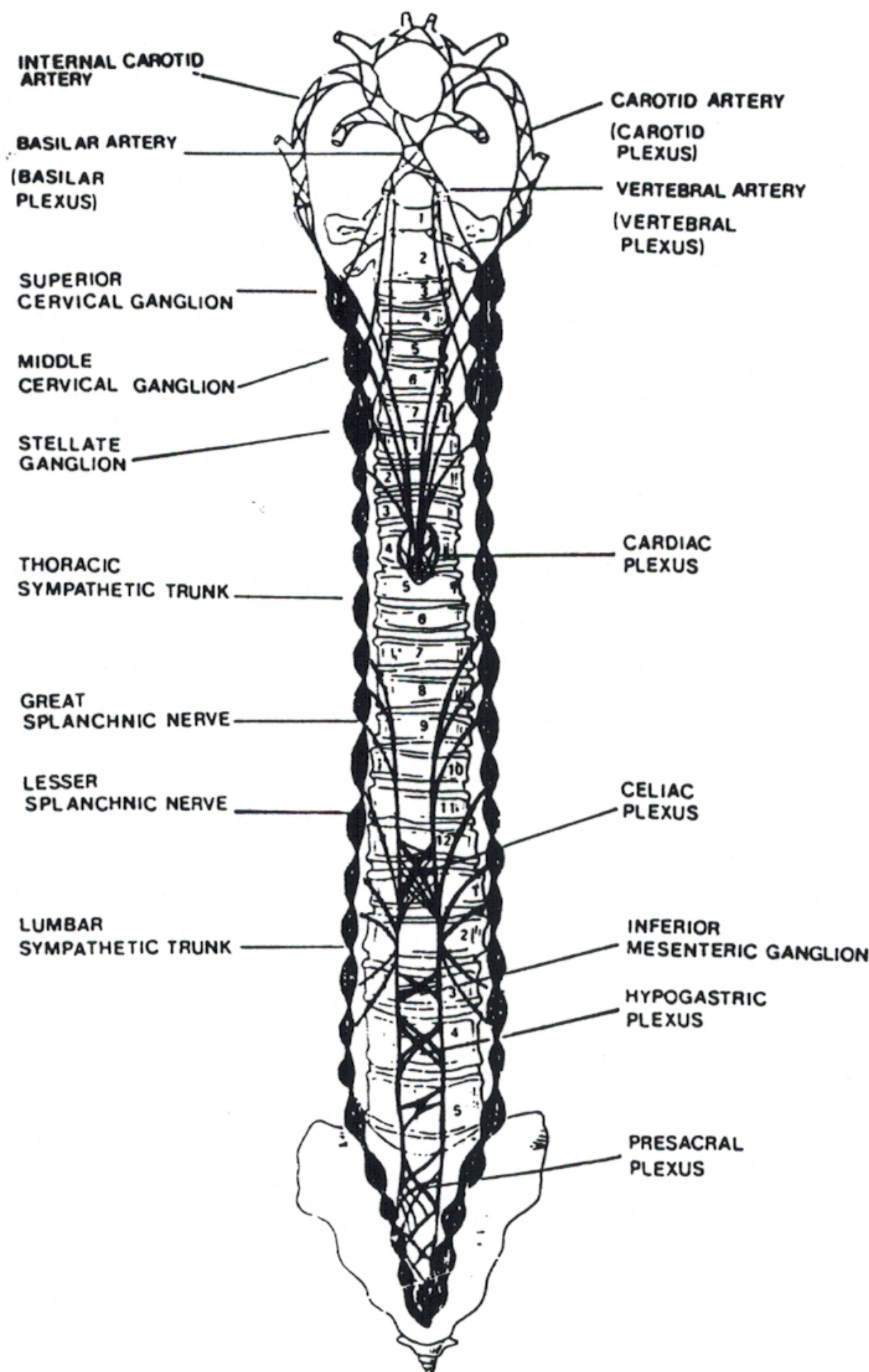


Fig. 3. Paravertebral chain of sympathetic ganglia facilitates the spread of the sympathetic impulse horizontally and vertically. This explains remote complications of reflex sympathetic dystrophy.

3. Modulation of the immune system by up- or down-regulating immune system response to any distress. The abnormal immune response leads to bouts of swelling, spontaneous bruises of skin, and fever. In the acute stage of the disease, the "helper" T-cell lymphocytes are elevated. In the chronic stage, the "killer" T cells are activated.

Sympathetically Maintained Pain versus Sympathetically Independent Pain

As outlined in Table 1, there are conditions that involve both somatic and sympathetic nerves. For example, in cervical or lumbar radiculopathy (nerve root injury) the majority of the pain is somatic in nature. However, in nerve root contusion both the somatic nerves, as well as sympathetic nerves, become injured, causing a combination of somatic and neuropathic pain. Another example is reflex sympathetic dystrophy. In this condition, the disease is usually caused by

a minor trauma selectively affecting the small and unmyelinated C fibers around the arterioles in the skin or the nerve trunk. In the acute stage, the pain is purely sympathetically mediated and is successfully and completely blocked by diagnostic sympathetic nerve block [5]. On the other hand, as the condition becomes chronic, longstanding vasoconstriction secondary to the sympathetic nerve irritation results in ischemic damage to the larger somatic (myelinated) sensory nerve fibers. In addition, application of ice as a therapeutic modality also selectively damages the myelinated sensory nerve fibers by causing a freezing effect on the fatty tissue of the myelin and secondarily causing damage and necrosis of the nerve fibers. The above traumatic vascular and hypothermic factors eventually result in involvement of the somatic nerves and origination of sympathetically independent pain. As a result, the sympathetic nerve block does not relieve the pain and the patient is improperly denied the proper diagnosis and treatment of reflex sympathetic dystrophy. The condition becomes more complicated by unnecessary operations when the disease is mistaken for carpal tunnel syndrome. Thermography is helpful to identify the sympathetic pathology and to help the clinician treat the patient with nerve blocks.

Diagnosis

The diagnosis of neuropathic pain is handicapped by multiple factors. The dynamic state of flux of the sympathetic system causes confounding temporal changes in the vital signs including surface temperature, which becomes very confusing. This principle causes multiple artifacts: physiologic artifacts, such as the effect of nicotine; technical artifacts, e.g., warm-room, or limited thermographic views, low sensitivity of thermal recording, etc; and preexisting pathology confusing the thermographic picture related to the latest condition being studied.

The main handicap with thermography is its extreme sensitivity. The disturbance of sympathetic function due to a lifelong history of minor traumas can leave "fingerprints" of sympathetic dysfunction that can be quite confusing.

As an example, a 55-yr-old man with a 2 yr history of work injury causing neuropathic nerve damage in the right median nerve distribution has a past history of preexisting asymptomatic cervical spondylosis with right fifth finger hypothermic changes on thermography. The same patient also has a past history of a congenital cerebral palsy complicated by attention deficit hyperactivity disorder. The cerebral palsy has left the patient with hyperthermia over the entire left side of the body due to anatomical arrest of development of the brain stem and the spinal cord. In such a confusing clinical picture, only a careful history taking can make sense out of the plethora of abnormalities discovered on the infrared thermography test.

The problem of the complexity of the sympathetic function and artifacts mentioned above has been compounded by the clinician's confusing anatomical with physiological tests, and expecting thermography to provide information obtained from anatomical tests such as X-ray, CT scan, or MRI.

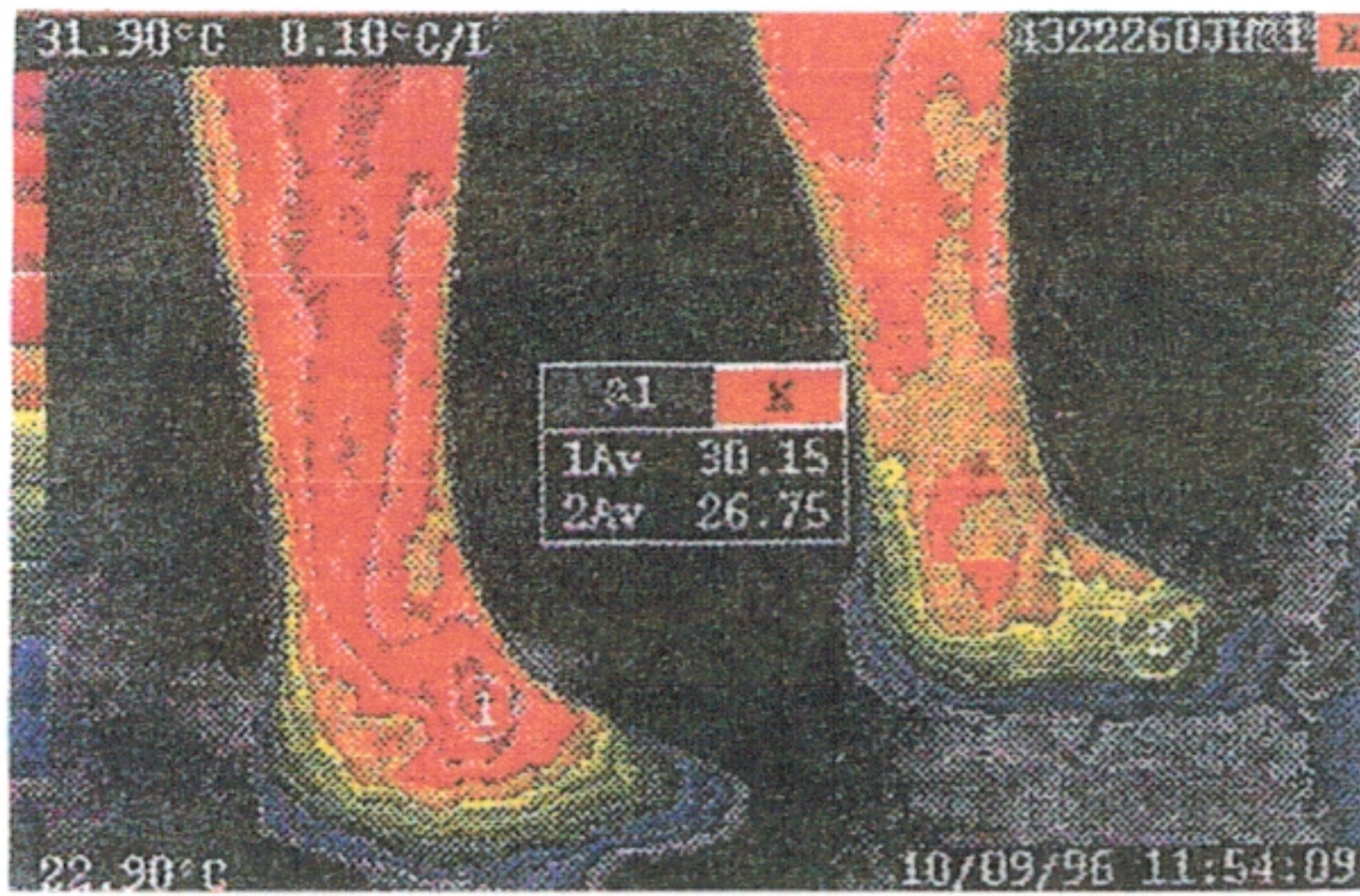


Fig. 4. "Virtual sympathectomy" due to repetitive right lumbar sympathetic nerve blocks, resulting in permanent damage and heat leakage in lower extremity (1). The patient was spared from further nerve blocks on the right side.

Other Diagnostic Tests

There has been an overemphasis on anatomical tests such as MRI for diagnosis of painful disorders. The standard study of pain in the spine or extremity starts with the MRI or CT scan test. If the MRI or CT scan does not show a disc pathology (which is responsible in only one-third of chronic pain patients), then the patient is accused of suffering from "soft-tissue injury" and imagining the pain. Some of the softest tissues in the body are the small unmyelinated C fibers that are almost exclusively responsible for neuropathic pain. Injury to these nerves does not cause any abnormality on X-ray, MRI, CT scan, or electromyographic nerve conduction velocity tests. A patient who suffers from acute heart attack should not be evaluated by anatomical tests such as X-ray, CT scan, or MRI. A simple ECG test is far more informative.

The improper preoccupation with intervertebral disc disease as an answer to every kind of chronic back pain has resulted in clinicians' ignoring other diseases such as nerve contusion or other types of neuropathic pain. Thermography objectively sheds light in such cases. As a result, thermography spares the patient from unnecessary disc surgery.

Electromyography and nerve conduction velocity test are quite informative in diagnosing the dysfunction of large myelinated nerve fibers. These tests are usually normal in neuropathic pain pathology. They usually cause confusion by coming up with the diagnosis of entrapment neuropathy, such as carpal tunnel or thoracic outlet syndrome, secondary to the inflammation accompanying the neuropathic pain.

The application of scintigraphic bone scan has been quite popular in the study of neuropathic pain of reflex sympathetic dystrophy. However, the extensive review of the literature by Lee and Weeks [6] has revealed a diagnostic sensitivity of no more than 55% for this test. Doppler ultrasound study of microcirculation sudomotor studies, quantitative sensory tests, autonomic tests [7], and sympathetic skin responses are limited by the fact that they provide information regarding a small area of the involved extremity.

Diagnostic Limitations of Thermography

In acute stages of sympathetic dysfunction, usually the extremity is hot, and gradually in the chronic stage, becomes

cold. However, in some more severe cases such as in the case of electrical injury, the damage is permanent enough to cause perpetuation of the hyperthermia even months or years after injury. Thermography shows an iatrogenic (caused by treatment) hyperthermia, which is usually irreversible and permanent (Fig. 1).

This is especially seen after frequent and repetitive ganglion nerve blocks resulting in a "virtual sympathectomy" (Fig. 3). A temperature difference of as little as 1° C between the two extremities is diagnostic of a definite sympathetic dysfunction. Such a hypersensitivity demands impeccable technique to exclude artifacts causing the temperature difference. For example, a patient cooling off in the lab with a temperature of 20° C may have a tendency to protect the area of the damaged hand with the warm area of the opposite-side armpit and cause artifactual focal hyperthermia.

The hyperthermic apex of the lesion may be found in a remote area away from the symptomatic extremity. An example is a nerve root contusion causing cold foot and focal hyperthermic damage to the sensory root in the L5 or S1 nerve roots in the paravertebral region of the lumbar spine. Another example is the symptomatic extremity that has undergone so many sympathetic ganglion nerve blocks that the extremity has become hyperthermic due to "virtual sympathectomy." The contralateral asymptomatic extremity shows marked hypothermia as a compensatory reflex. This results in an abnormal demographic picture, pointing to the normal extremity as a source of pain (Fig. 1).

The thermatomal distribution of the sympathetic temperature change usually causes regional abnormality in the distribution of brachial, femoral, or carotid arteries (Fig. 2), which, along with sensory loss in the same distribution, results in misdiagnosis of malingering, hysteria, or "non-anatomical" sensory loss.

Clinical Applications

Thermography can be valuable both as a diagnostic tool and as a therapeutic guide. As is the case with all branches of medicine, laboratory tests rarely point to a pathology with absolute certainty. The anatomical or physiological tests only show the area of abnormality. The most accurate diagnostic tool is careful history taking. Such a clinical history will orient the clinician regarding the relevancy of the abnormal test, or the meaning and nature of the abnormality found on the test.

If the thermography already shows a "virtual sympathectomy" (Fig. 4) due to previous multiple invasive sympathetic ganglion nerve blocks, or due to previous surgery or severe trauma, the patient is spared from unnecessary repetition of nerve blocks. In an unusual form of neuropathic pain called "reflex sympathetic dystrophy," the disease is invariably accompanied by severe emotional and psychological abnormalities. As a result, the condition is mistaken for anxiety, malingering, hysteria, even Munchausen syndrome (a euphemism for calling the patient a liar). The standard practice for diagnosis of reflex sympathetic dystrophy is bone scintigraphy scanning. However, a comprehensive review of literature by Lee and Weeks [6] proved that bone scan is diagnostic in only 55% of reflex sympathetic dystrophy

patients. Unfortunately, in spite of this fact, practically half of reflex sympathetic dystrophy patients are denied diagnosis and treatment because of negative bone scan. The sensitivity and specificity of thermography has been reported within the 80 percentile range [8].

Diagnosis of Reflex Sympathetic Dystrophy

In relation to reflex sympathetic dystrophy with other types of neuropathic pain (Table 1), it becomes obvious that no disease other than reflex sympathetic dystrophy meets the strict four criteria mentioned above. This raises the question, why bother performing thermography if the four principles have already made the diagnosis? The reason for thermography is to identify the areas of nerve damage (focal hyperthermia) to avoid incurring further injury to the areas of sympathetic nerve damage.

Infrared thermography provides vital information that contributes to more accurate understanding and diagnosis of the disease in each patient, and spares a lot of patients from unnecessary invasive treatments such as surgical procedures. Realizing that every reflex sympathetic dystrophy patient demonstrates the neuropsychological manifestations of the disturbance of the limbic system, thermography differentiates such patients from others suffering from neuropsychological disturbances due to environmental, hormonal, or other iatrogenic (side effects of treatment) emotional disturbances.

Conclusion

Infrared thermography is a sensitive test that requires impeccable technique. It shows any old or new dysfunction of the

sympathetic system. Without a careful history taking and clinical correlation, the old and new infrared thermography changes are too confusing to interpret. In neuropathic pain, the MRI, CT scan, electromyography, and nerve conduction times are usually normal because the pathology involves small unmyelinated thermal and mechanosensory nerve fibers, which cannot be studied by the above-mentioned tests. Infrared thermography helps the clinician arrive at the proper, accurate diagnosis.

Infrared thermography can guide the treating physician as to the area that needs treatment. A hyperthermic lesion pointing to irreversible sympathetic nerve damage precludes unnecessary sympathetic nerve blocks, sympathectomy, or surgical exploration.

References

1. Kowalski ML, Kaliner MA: Neurogenic inflammation, vascular permeability, and mast cells. *J Immunol* 1988;140:3905-3911
2. Benarroch EE: The central autonomic network: Functional organization, dysfunction, and perspective. *Clinic Proc* 10:988-1001
3. Lenz FA, Gracely RH, et al: The sensory-limbic model of pain memory. *Pain Forum* 1997;6:22-31
4. Hooshmand H: *Chronic Pain. Reflex Sympathetic Dystrophy*. Boca Raton, FL, CRC Press, 1993, pp 62-63
5. Treed RD, Raja SN, et al: Evidence that peripheral alpha adrenergic receptors mediate sympathetically mediated pain. In Bond MI, Charlton JE, Woolf CJ (eds): *Proceedings of the Sixth World Congress on Pain*. Amsterdam, Elsevier Science, 1997, pp 377-382
6. Lee GW, Weeks PM: The role of bone scintigraphy in diagnosing reflex sympathetic dystrophy. *J Hand Surg* 1995;20A:458-463
7. Chelimsky TC, Low PA, Naessens JM: Value of autonomic testing in RSD. *Mayo Clin Proc* 1995;70:1029-1040
8. Wexler CE, Chafez N: Cervical, thoracic, and lumbar thermography in the evaluation of sympathetic workers' compensation patients—a study. *Modern Medicine. Special Supplement: Academy of Neuromuscular Thermography Clinical Proceedings* 1987;55:53-57