

INTERNATIONAL RSD FOUNDATION

"Dedicated to Helping RSD-CRPS Patients Worldwide"

This quick reference guide was created to help educate RSD-CRPS patients, their family, friends, and the medical community.

This reference guide will give you a quick insight into the signs, symptoms, treatment and the management of RSD-CRPS. We hope this information will be helpful to you.

Please feel free to share this reference guide with your family, friends, and the medical community.

About RSD-CRPS

H. Hooshmand, M.D. (Retired) and Eric M. Phillips

Source: www.rsinfo.com and www.rsdRx.com

What is RSD/CRPS?

Reflex Sympathetic Dystrophy (RSD), more recently known as Complex Regional Pain Syndrome (CRPS) is a disease brought on by damage or trauma to the Sympathetic Nervous System. It can be brought on by an accident, as in my case, minor trauma or surgery (i.e., arthroscopy of the knee or shoulder, carpal tunnel surgery, disc herniation surgery, removal of neuroma, rib resection, tarsal tunnel surgery, ulnar nerve surgery, etc.)

There are four stages of RSD/CRPS:

- Stage I -Dysfunction
- Stage II - Dystrophy
- Stage III - Atrophy
- Stage IV - Irreversible, Failure of the Immune system

RSD-CRPS REFERENCE GUIDE

Below are some of the symptoms of RSD/CRPS:

- Burning pain in the extremities
- Chronic pain after injury or surgery
- Cold feeling in the extremities
- Discoloration of the skin
- Edema (Swelling of the extremities)
- Hypersensitivity to touch
- Limited range of motion
- Muscle spasms

Below are some treatments to avoid:

- Amputation
- Application of ice
- Chemical sympathectomy (i.e., Alcohol nerve block, Phenol nerve block)
- Improper nerve blocks (i.e., Repetitive stellate ganglion nerve blocks)
- Radiofrequency sympathectomy
- Spinal cord stimulators (SCS)
- Surgical sympathectomy
- Unnecessary surgery

As, you can see these symptoms are varied and unique. Reflex Sympathetic Dystrophy (RSD/CRPS) can be in the upper extremities and lower extremities. There have also been many reported cases of facial and total body RSD/CRPS.

History of CRPS

Hooshmand H, Phillips EM. Various Complications of Complex Regional Pain Syndrome (CRPS) Source: www.rsinfo.com and www.rsdRx.com

HISTORY OF CRPS

The various symptoms that make up CRPS, and later, the formal naming of this medical condition, have been well documented throughout history. Ambroise Pare was one of the first to describe what is now called CRPS, through his account of the persistent pain that King Charles IX had suffered from in the 16th century (1). In the late 1700's British surgeon Sir Pervcivall Pott recognized burning pain and atrophy in injured extremities (2, 3). In 1813 Denmark reported a single case of a soldier who had an amputation due to burning pain (2, 4,5). In 1838 Hamilton had seen some cases in which his patients had symptoms of causalgia which resulted from accidental nerve injuries (6). Early in 1864 Paget had patients who had symptoms of constant warmth in their limb after nerve injury (7). Also, in 1864 Silas Weir Mitchell the father of American neurology gave the description of causalgia in his classic article Gunshot Wounds and Other Injuries of Nerves, but it was not until 1867 when he coined the term of causalgia from the Greek words, "Kausos" (heat) and "algos" (pain) to describe this syndrome (8). Since Mitchell's first description of this painful syndrome, there have been many other names giving to this awful disease. In 1900 Sudek named it Sudeck atrophy; in 1937 DeTakats named it Reflex Dystrophy; in 1947 Steinbrocker named it Reflex Neurovascular Dystrophy and Shoulder-Hand Syndrome; in 1947 Evans named it Reflex Sympathetic Dystrophy (RSD); and in 1994 Merskey, et al. named it Complex Regional Pain Syndrome (CRPS) (9-14).

References

1. Paré A. Les Ouvres d' Ambroise Paré, King Charles IX. 10th Book, Chapter 41. Paris Gabriel Buon 1598: 401.
2. Hooshmand H: Chronic Pain: Reflex Sympathetic Dystrophy: Prevention and Management. CRC Press, Boca Raton FL. 1993. www.rsdRx.com
3. Casten DF, Betcher AM. Reflex sympathetic dystrophy. Surg Gynecol Obstet 1955; 100: 97–101.

RSD-CRPS REFERENCE GUIDE

4. Denmark A. An example of symptoms resembling tic douloureux produced by a wound in the radial nerve. *Med Chir Trans* 1819; 4:48.
5. Richards RL. Causalgia: a centennial review. *Arch Neurol* 1967; 16:339.
6. Hamilton, J. On some effects resulting from wounds of nerves. *Dublin J Med Sc* 1838; 13: 38–55.
7. Paget J. Clinical lecture on some cases of local paralysis. *Med Times Hosp Gaz* 1864; 1:331.
8. Mitchell SW, Morehouse GR, Keen WW. *Gunshot wounds and other injuries of nerves*. Philadelphia: Lippincott, 1864.
9. Sudeck P. Ueber die acute entzündliche Knochenatrophie. *Arch Klin Chir* 1900; 62:147–156. German.
10. DeTakats, G. Reflex dystrophy of the extremities. *Arch Surg* 1937; 34: 939–956.
<http://archsurg.jamanetwork.com/article.aspx?articleid=54314218>
11. Steinbrocker, O. *Annals of the Rheumatic Diseases*, 1947;6,80.
<http://annals.org/article.aspx?articleid=673834>
12. Evans JA. Reflex sympathetic dystrophy; report on 57 cases. *Ann Intern Med* 1947;26: 417-426. <http://annals.org/article.aspx?articleid=673543>
13. Merskey H, Bogduk N. *Classification of chronic Pain Descriptions of Chronic Pain Syndromes and Definitions of Pain Terms*. Task Force on Taxonomy of the International Association for the Study of Pain. Merskey, H. editor. IASP Press. Seattle 1994.
<http://www.iasppain.org/files/Content/ContentFolders/Publications2/FreeBooks/Classification-ofChronic-Pain.pdf>
14. Hooshmand H, Phillips EM. Various Complications of Complex Regional Pain Syndrome (CRPS) www.rsinfo.com and www.rsdrx.com

Complex Regional Pain Syndrome (CRPS)

Hooshmand H, Phillips EM. Various Complications of Complex Regional Pain Syndrome (CRPS) Source: www.rsinfo.com and www.rsdRx.com

Complex regional pain syndrome (CRPS) is an unrelenting pain syndrome that affects millions of people world-wide. Most patients display the common signs and symptoms of CRPS.

When patients have suffered for many years to decades, they may develop many various complications of the disease.

There are various ways CRPS can develop. Onset of this disease is usually caused by a minor trauma, soft-tissue injury (i.e., sprain ankle or wrist); other such causes are crush injuries, surgery, repetitive stress injury (RSI), electrical injuries (EI), and in some cases venipuncture injury (VP CRPS II). Spread of the disease and internal organ involvement has also been reported in many patients who suffer from late stages of the disease (1).

CRPS is a definitive chronic pain syndrome which is associated with multiple manifestations and complications which makes this disease very difficult to treat. The frontline treatment option for most patients, after a clinical diagnose of CRPS is with a stellate ganglion nerve block (SGB). This type of nerve block can be helpful with the initial diagnoses of CRPS. When SGB are done repetitively they can cause more harm to the patient. Safer and more effective types of nerve blocks such as epidural nerve blocks (ENB), caudal blocks, and paravertebral nerve blocks (PNB) that can be more beneficial in the management of CRPS treatments (2).

References

1. Hooshmand H, Phillips EM. Various Complications of Complex Regional Pain Syndrome (CRPS) www.rsdRx.com and www.rsinfo.com
2. Hooshmand H, Phillips EM. Epidural Nerve Blocks (ENB) in the Treatment of Complex Regional Pain Syndrome (CRPS) www.rsdRx.com and www.rsinfo.com

Psychological Aspects of RSD(CRPS)

Hooshmand H, Phillips EM. Psychological Aspects of Reflex Sympathetic Dystrophy (RSD) Complex Regional Pain Syndrome (CRPS)

Source: www.rsdrx.com and www.rsdinfo.com

In, Doctor Hooshmand's review of 824 RSD (CRPS) patients, one or more of the limbic system dysfunctions were present in every case except three (1).

These consisted of insomnia (92%), irritability, agitation, anxiety (78%), (depression (73%), poor memory and concentration (48%), poor judgment (36%), and panic attacks (32%).

Understanding the nature of emotional components of RSD (CRPS) spares the patient from misdiagnosis and improper treatment (1).

Doctor Mary Lynch reviewed the subject of psychological aspects of RSD (CRPS) (2). Her conclusion was "There is general agreement that profound emotional and behavioral changes can follow these types of pain.

Opinions have varied widely on the issue of psychological etiology. It has often been suggested that certain personality traits predispose one to develop sympathetically related pain syndromes.

A review of the literature reveals no valid evidence to substantiate this claim." On the other hand, De Good et al found patients suffering from RSD (CRPS), when compared to patients suffering from back pain and headaches, had the highest level of pain intensity, but demonstrated relatively less emotional distress (3, 4).

References

1. Hooshmand H., Hashmi M. Complex regional pain syndrome (Reflex sympathetic dystrophy syndrome): Diagnosis and Therapy - A Review of 824 Patients. Pain Digest 1999; 9: 1-24.
2. Lynch ME. Psychological aspects of reflex sympathetic dystrophy: a review of the adult and pediatric literature. Pain 1992; 49: 337-47.

RSD-CRPS REFERENCE GUIDE

3. De Good DE, Cundiff GW, Adams LE, et al. A psychosocial and behavioral comparison of reflex sympathetic dystrophy, low back pain, and headache patients. *Pain* 1993; 54: 317-22.

4. Hooshmand H, Phillips EM. Psychological Aspects of Reflex Sympathetic Dystrophy (RSD) Complex Regional Pain Syndrome (CRPS)
www.rsdrx.com and www.rsinfo.com

Spread of CRPS

Hooshmand H, Phillips EM. Spread of Complex Regional Pain Syndrome (CRPS)

Source: www.rsdrx.com and www.rsinfo.com

The spread of CRPS in vertical or horizontal fashion (upper and lower extremities, or both upper or both lower extremities) has been recognized ever since 1976 (1). The surgical procedure facilitates the spread of the CRPS (2).

More recently, the phenomenon of the spread of the disease has been proven by Schwartzman, et al (3,4).

The chain of sympathetic ganglia from base of the skull to sacral regions on the right and left sides, spread the pathologic impulse to other extremities (5).

The phenomenon of referred pain should not be mistaken for spread of the disease.

CRPS is not usually limited to one part of an extremity or one extremity. Usually, the pathological sympathetic function spreads to adjacent areas (5).

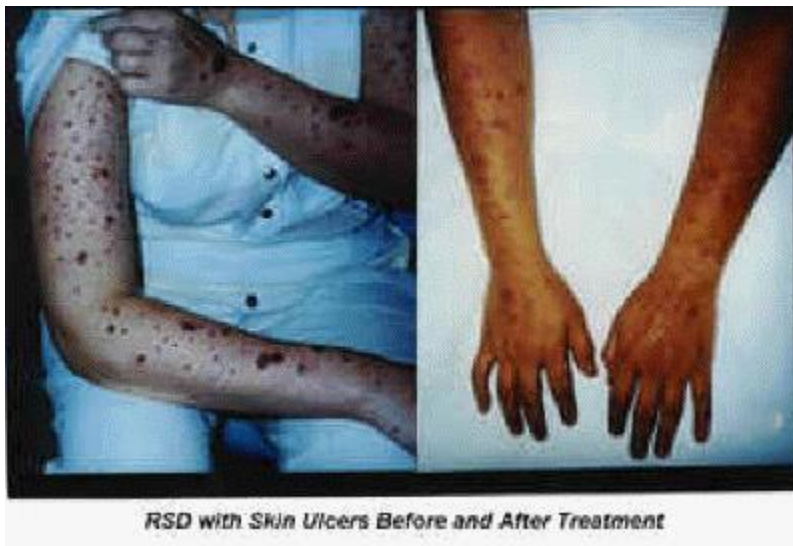The usual factors facilitating the spread of the disease are surgical procedures, application of ice, and stress of too much activity or inactivity (3).

RSD-CRPS REFERENCE GUIDE

In, Doctor Hooshmand's review study of 824 CRPS patients, the number one aggravator was cryosurgery, followed by surface cryotherapy applied more than two months. The surface cryotherapy less than two months did not show the tendency for spread of CRPS (3,6).

CRPS invariably involves the internal organs. Usually the skin surface is cold at the expense of increased circulation to the internal organs. This increased circulation can cause osteoporosis, fractures of bone, abdominal cramps and diarrhea, disturbance of absorption of foods with resultant weight loss, water retention with aggravation of premenstrual headaches and depression, persistent nausea and vomiting, as well as severe vascular headaches mistaken for "cluster headache".

In treating CRPS, even if the opposite extremity looks normal, the treatment should be given to both extremities because of this principle of bilateral innervation.



The CRPS had spread in this patient to both hands and arms. She suffered for many years with severe lesions on both hands and arms. Treatment with I.V. Mannitol helped heal the lesions.

RSD-CRPS REFERENCE GUIDE

References

1. Kozin F, McCarty DJ, Sims J, Genant H. The reflex sympathetic dystrophy syndrome. I. Clinical and histologic studies: evidence of bilaterality, response to corticosteroids and articular involvement. *Am J Med* 1976; 60:321-331.
2. Radt P. Bilateral reflex neurovascular dystrophy following a neurosurgical procedure. Clinical picture and therapeutic problems of the syndrome. *Confinia. Neurol* 1968; 30 (5): 341-348.
3. Schwartzman RJ. Reflex sympathetic dystrophy. *Handbook of Clinical Neurology. Spinal Cord Trauma*, H.L. Frankel, editor. Elsevier Science Publisher B.V. 1992; 17: 121-136.
4. Maleki J, LeBel AA, Bennett GJ, Schwartzman RJ. Patterns of Spread of complex regional pain syndrome, type I (reflex sympathetic dystrophy). *Pain* 2000; 88: 259-266.
5. Hooshmand H. Chronic pain: reflex sympathetic dystrophy. Prevention and management. Boca Raton, FL: CRC Press, 1993; pp 1-202.
6. Hooshmand, H., Hashmi, M., Phillips, E.M.: Cryotherapy can cause permanent nerve damage: A case report. *AJPM* 2004; 14: 2: 63-70.

Stages of CRPS

Hooshmand H, and Hashmi M. Complex Regional Pain Syndrome-Reflex Sympathetic Dystrophy Syndrome: Diagnosis and Therapy - A Review of 824 Patients (Pain Digest- 1999; 9:1-24) Source: www.rsdrx.com

STAGES OF CRPS/RSD

CRPS/RSD has been divided into different stages. Depending on nature of injury, the stages vary in their duration. In the 17 patients suffering from venipuncture CRPS in our series, deterioration from stage I to stage III was measured in a few weeks up to less than 9 months. This is in contrast with CRPS in children in whom stages would stagnate, reverse or improve slowly.

In STAGE I, is a sympathetic dysfunction with typical thymatomal distribution of the pain. The pain may spread in a mirror fashion to contralateral extremity or to adjacent regions on the same side of the body. In stage one; the pain is usually SMP in nature.

In STAGE II, the dysfunction changes to dystrophy manifested by edema, hyperhidrosis, neurovascular instability with fluctuation of livedo reticularis and cyanosis - causing change of temperature and color of the skin in matter of minutes. The dystrophic changes also include bouts of hair loss, ridging, dystrophic, brittle and discolored nails, skin rash, subcutaneous bleeding, neurodermatitis, and ulcerative lesions. Due to the confusing clinical manifestations, the patient may be accused of factitious self-mutilation and "Münchhausen syndrome." All these dystrophic changes may not be present at the same time nor in the same patient. Careful history taking is important in this regard.

In STAGE III, the pain is usually no longer SMP and is more likely a sympathetically independent pain (SIP). Atrophy in different degrees is seen. Frequently, the atrophy is overshadowed by subcutaneous edema. The complex regional pain and inflammation spread to other extremities in approximately 1/3 of CRPS patients.

At stage II or III it is not at all uncommon for CRPS to spread to other extremities. At times, it may become generalized. The generalized CRPS is an infrequent late stage complication. It is accompanied by sympathetic dysfunction in all four extremities as well as attacks of headache, vertigo, poor memory, and poor concentration. The spread through paravertebral and midline sympathetic nerves may be vertical, horizontal, or both. The original source of CRPS may sensitize the patient to later develop CRPS in another remote part of the body triggered by a trivial injury. The ubiquitous phenomenon of referred pain to remote areas (e.g., from foot or hand to spine) should not be mistaken for the spread of CRPS.

RSD-CRPS REFERENCE GUIDE

At STAGE III, inflammation becomes more problematic and release of neuropeptides from c-fiber terminals results in multiple inflammatory and immune dysfunctions. The secondary release of substance P may damage mast cells and destroy muscle cells and fibroblasts.

STAGE IV:

1. Failure of the immune system, reduction of helper T-cell lymphocytes and elevation of killer T-cell lymphocytes.
2. Intractable hypertension changes to orthostatic hypotension.
3. Intractable generalized edema involving the abdomen, pelvis, lungs, and extremities.
4. Ulcerative skin lesions which may respond to treatment with I.V. Mannitol, I.V. Immunoglobulin, and ACTH treatments. Calcium channel blockers such as Nifedipine may be effective in treatment.
5. High risks of cancer and suicide are increased.
6. Multiple surgical procedures seem to be precipitating factors for development of stage IV.

Stage IV is almost the flip side of earlier stages, and points to exhaustion of autonomic and immune systems. Ganglion blocks in this stage are useless, and treatment should be aimed at improving the edema and the failing immune system. Sympathetic ganglion blocks, alpha blockers, including Clonidine, are contraindicated in stage IV due to hypotension. Instead, medications such as Proamantin (midodrin) are helpful to correct the orthostatic hypotension (1).

1. Hooshmand H, and Hashmi M. Complex Regional Pain Syndrome-Reflex Sympathetic Dystrophy Syndrome: Diagnosis and Therapy - A Review of 824 Patients (Pain Digest- 1999; 9:1-24) www.rsdrx.com

Management of CRPS

THE MANAGEMENT OF COMPLEX REGIONAL PAIN SYNDROME (CRPS)

H. Hooshmand, M.D.(Retired) and Eric M. Phillips

Source: www.rsdrx.com and www.rsinfo.com

The first step in the management of complex regional pain syndrome (CRPS) is coming to the arrival at an accurate diagnosis. CRPS is diagnosed by inclusion and not by exclusion. No laboratory tests can diagnose CRPS 100% of the time.

RSD-CRPS REFERENCE GUIDE

The use of scintigraphic triphasic bone scans (STBS) may help diagnose CRPS in approximately 55% of the cases in the first six months (1). The research of Chelimsky et al., found STBS to be abnormal in no more than 25% of CRPS patients (2).

The use of infrared thermal imaging (ITI) is useful in the diagnosis and management of CRPS pain.

It provides an overall picture of temperature changes in superficial and deep structures (27 mm) (3-5). ITI provides useful clinical information when applied with proper technique. It provides diagnostic and therapeutic information limited to diseases involving autonomic, neurovascular, and neuroinflammatory changes (3,6,7).

CRPS is a clinical diagnosis corroborated by test such as laser doppler, STBS, and ITI. Early diagnosis is essential for successful treatment of CRPS (8-11).

CRPS patients should be diagnosed early, treated early; the treatment should be multi-disciplinary and affirmative. The only hope for the patient is better education of the physicians in regards to the mechanism of CRPS, and the importance of early diagnosis, early physical therapy, and the use of nerve blocks, as well as detoxification from harmful medications.

Also, it is important to spare the patient from unnecessary surgical procedures that can cause more pain and spread of CRPS.

There are no standardized diagnostic methods and no universal treatment plan that have been available, and the success rate of the treatment has been quite low.

At the present time there are enough methods available to keep these patients comfortable and give them a better quality of life.

References

1. Lee GW, Weeks PM. The role of bone scintigraphy in diagnosing reflex sympathetic dystrophy. *J Hand Surg [Am]*. 1995; 20:458-463.
2. Chelimsky T, Low PA, Naessens JM, et al. Value of autonomic testing in reflex sympathetic dystrophy. *Mayo Clinic Proceedings* 1995; 70:1029-1040.
3. Hooshmand H, Hashmi M, Phillips EM. Infrared thermal imaging as a tool in pain management - An 11-year study, Part I of II. *Thermology International* 2001; 11: 53-65.
4. Lawson RN. Thermography- a new tool for the investigation of breast lesions. *Can Med Assoc J* 1957; 13:517-524.
5. Ring EFJ. Progress in the measurement of human body temperature. *IEEE Engineering in Medicine and Biology*. July/August 1998; 19-24.

6. Hooshmand H. Is thermal imaging of any use in pain management? *Pain Digest* 1998; 8:166-170.
7. Hooshmand H, Hashmi M, Phillips, EM. Infrared thermal imaging as a tool in pain management - An 11- year study, Part II: Clinical Applications. *Thermology International* 2001; 11: 1-13.
8. Hooshmand H. Chronic Pain: Reflex Sympathetic Dystrophy: Prevention and Management. CRC Press, Boca Raton FL. 1993.
9. Payne R. Neuropathic pain syndromes with special reference to causalgia and reflex sympathetic dystrophy. *Clin J Pain*. 1986; 2: 59-73.
10. Rowlingson JC. The sympathetic dystrophies. *Int Anesthesiol Clin* 1983; 21: 117-119.
11. Hooshmand, H. and Phillips EM. The Management of Complex Regional Pain Syndrome (CRPS) Source: www.rsdrx.com and www.rsinfo.com

Epidural Nerve Blocks for CRPS

Hooshmand H, Phillips, EM. Epidural Nerve Blocks (ENB) in the Treatment of Complex Regional Pain Syndrome (CRPS)

Source: www.rsdrx.com and www.rsinfo.com

EPIDURAL NERVE BLOCKS (ENB)

The reason for the administration of an epidural nerve block (ENB) in the treatment of CRPS is the fact that the pathology is chronic and it affects both the sympathetic and somesthetic systems.

This type of nerve block does help relieve the pain and helps improve the circulation in the target area. ENB are applied by insertion of the needle into the epidural space (the space between the spinal cord and the spinal canal). ENB are performed under the use of fluoroscopy (x-ray) guidance. After the epidural space is identified, a combination of four-fifths Marcaine local anesthetic and a minuscule amount of Depo-Medrol® is injected in the epidural space (1). Depo-Medrol® itself consists of a large inert and innocuous protein attached to a small amount of Methylprednisolone. The local anesthetic Marcaine relieves the pain, and the small amount of corticosteroid attached to the protein reduces the inflammation (7).

STELLATE GANGLION BLOCKS (SGB)

According to the late Doctor Bonica who is considered the father of chronic pain management, as he specifies in his book, the use of stellate ganglion blocks (SGB) in the best of hands (which would be Doctor Bonica) has a 25% rate of failure (2). This is because the stellate ganglion has a very vague anatomical structure which is different from patient to patient.

So, it usually takes a few or several sticks before the ganglion block is done. A truly successful stellate ganglion block is accompanied by Horner's syndrome (oculosympathetic paralysis) (3,4). A Horner's syndrome is successfully achieved in around 75% of the patients who undergo the block. It also has other serious complications which would be harmful to the patients (3,4).

The worst feature of the SGB is the fact that repeated SGB result in the bombardment and traumatic needle damage to the stellate ganglion sympathetic nerve cells. God created those nerve cells not to be needled and destroyed. Quite frequently, after several SGB, the patient develops sympathetically independent pain (SIP) in a patient who before the ganglion blocks had sympathetically maintained pain (SMP). This confuses the clinician and because a successful block doesn't help the patient anymore, the patient is accused of being a malingerer or not having "CRPS anymore". Frequently in such patients the hand and forearm become warm and stay warm because of the virtual sympathectomy due to the needling of the stellate ganglion (Figure. 1) (5-9).

The use of sympathetic ganglion blocks (SGB) are not helpful in cases with late stage CRPS. This is because the patient's pain is no longer sympathetically maintained pain (SMP), but rather the pain is now sympathetically independent pain (SIP).

Treatment for late stages of CRPS should consist of using ENB, PNB, and trigger point injection as safer alternatives to using repetitive SGB in the management of CRPS. If we move forward according to the current concepts of diagnosis and management of CRPS. The patients are doomed to be in severe chronic pain due to the lack of proper treatment.

RSD-CRPS REFERENCE GUIDE

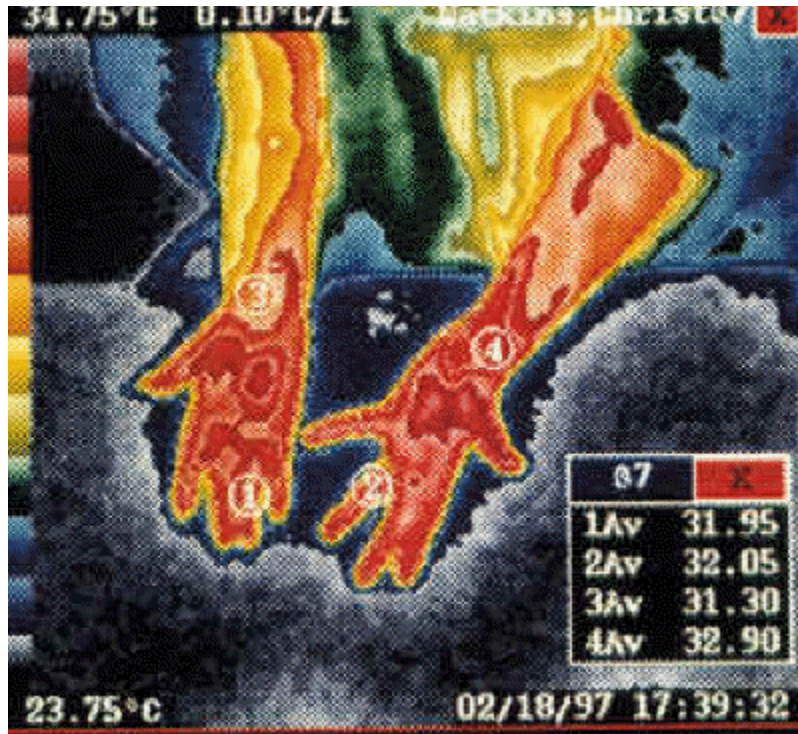


Figure 1. More than two dozen stellate ganglion blocks (SGB) to each side have damaged enough sympathetic nerve to cause permanent hyperthermia as the manifestation of virtual sympathectomy. Further blocks have no diagnostic or therapeutic value. With the use of infrared thermal imaging (ITI), it spared the patient from further sympathetic nerve blocks (4).

References

1. Hooshmand H, Phillips EM. The management of complex regional pain syndrome (CRPS). www.rsdrrx.com and www.rsdinfo.com
2. Bonica JJ: The Management of Pain. Lea & Feibger Philadelphia. 1990; Vol. 1: p 229.
3. Elias M. Cervical Sympathetic and Stellate Ganglion Blocks. Pain Physician 2000; 3: (3)294-304.
4. Amhaz HH, Manders L, Chidiac EJ, et al. Unusual case of contralateral Horner's syndrome following stellate-ganglion block: a case report and review of the literature. Local Reg Anesth. 2013; 6: 31–33.
5. Hooshmand H, Hashmi H: Complex regional pain syndrome (CRPS, RSDS) diagnosis and therapy. A review of 824 patients. Pain Digest. 1999; 9: 1-24. www.rsdrrx.com
6. Hooshmand H: Is thermal imaging of any use in pain management? Pain Digest. 1998; 8:166-170. www.rsdrrx.com

RSD-CRPS REFERENCE GUIDE

7. Hooshmand, H., Hashmi, M, Phillips, E.M. Infrared thermal imaging as a tool in pain management. An 11-year study", Part I of II, Thermology International April 2001; 11: (2): 53-65. www.rsdRx.com and www.rsDinfo.com
8. Hooshmand H, Hashmi M, Phillips, EM. Infrared thermal imaging as a tool in pain management. An 11- year study, Part II: Clinical Applications. Thermology International 2001; 11: 1-13. www.rsdRx.com and www.rsDinfo.com
9. Hooshmand H, Phillips, EM. Epidural Nerve Blocks (ENB) in the Treatment of Complex Regional Pain Syndrome (CRPS) www.rsdRx.com and www.rsDinfo.com

Diet and RSD-CRPS

Hooshmand H. Chronic Pain: Reflex Sympathetic Dystrophy: Prevention and Management. CRC Press, Boca Raton FL. 1993. Source: www.rsdRx.com

Most CRPS patients have a problem with either weight gain or weight loss after developing the disease. The majority of clinicians do not consider eating habits important in CRPS patients, certain foods such as chocolate (which contains phenyletholamine and it directly stimulates the formation of dopamine and norepinephrin), hot dogs, and foods rich in tyrosine (red meats) which is the precursor of norepinephrine should be avoided. We devised this method of behavior modification more than 17 years ago.

This diet is not aimed at losing or gaining weight. It excludes foods that are harmful to your health and aggravate chronic pain (i.e., Five C's: cookies, cakes, chocolate, cocktails and candy. Other foods to avoid are internal organ meats such as Liver, sausage, and hot dogs). It also emphasizes the intake of foods that help the inhibitory nerve cells that suppress the pain input (4 F's: Fresh fruit, fresh vegetables, fish, and fowl) (1). By doing so, the patient's weight normalizes itself automatically: overweight or underweight extremes normalize close to the patient's ideal weight (1,2).

References

1. Hooshmand H. Chronic Pain: Reflex Sympathetic Dystrophy: Prevention and Management. CRC Press, Boca Raton FL. 1993.
2. Hooshmand H. and Phillips EM. Various Complications of Complex Regional Pain Syndrome (CRPS) www.rsdRx.com and www.rsDinfo.com

Physical and Massage Therapy

Physical Therapy Part -II

H. Hooshmand, M.D.

Neurological Associate Pain Management Center

Source: www.rsdrx.com

The best physical therapy for CRPS patients is alternating resting and activity without exhausting themselves. The patient should be taught that in CRPS/RSD, no pain is all gain. This is just a sharp contrast to the somatic pain where no pain is no gain.

The patient should learn to listen to their body, and the moment they start having pain because of prolonged sitting or standing, or prolonged bed rest, or prolonged activity, the patient should change position and stop the activity that is generating the pain. The general rule of thumb is sitting for 15-20 minutes, standing for 10-15 minutes, walking for 10-15 minutes, and lying down at least every few hours.

The patient should understand that resting for long hours is going to be as much if not more harmful than doing too much activity. If the patient wakes up in the middle of the night because of pain or discomfort, he or she should not just lay in bed. The patient should get out of bed and walk around.

The patient will be surprised how soon the pain improves by walking after long periods of rest. Anytime the patient is doing physical therapy or hydrotherapy, all the activities should be on both sides.

The patient should not apply the treatment only on the side of the body that is painful. The main reason being is that the nerves for temperature control of the body start from the central nervous system and go all the way down to the spinal cord.

So, if the patient has a lateralized pain, spasm, or limitation of motion, the exercises should be done on both sides, otherwise there would be a temperature asymmetry causing improvement to temperature on one side at the expense of the other side becoming colder. This type of bilateral exercise also prevents spread of CRPS.

MASSAGE THERAPY

H. Hooshmand, M.D.

Neurological Associate Pain Management Center

Source: www.rsdrx.com

Massage therapy is practically indispensable for the treatment of CRPS/RSD, especially if the patient is undergoing trigger point injections, occipital nerve blocks, and paravertebral nerve blocks. Applying massage therapy immediately after having the above-mentioned nerve blocks disseminates the irritating chemicals (e.g., nitric oxide, substance P, and CGRP) away from the area that the nerve block insertion has released the encapsulated chemicals and thus helps the elimination of the irritating chemicals by massage as well as application of moist heat.

This is similar to trying to clean a swimming pool that has not been touched for a year. Obviously, the pool is full of residuals of chemicals that have been accumulated in the pool. It is not enough to partially clean the toxic chemicals, but it also needs the flushing of the chemicals out of the pool.

The massage does the job of flushing of the chemicals out of the encapsulated areas making the chemicals accessible to capillaries, which absorb the chemicals and excrete them through the kidneys.

Medical Necessity of Massage Therapy After Nerve Blocks

Nerve blocks are aimed at relieving pain at the site of nerve irritation. Injection of local anesthetics combined with anti-inflammatories relieves the pain at the site. The nerve blocks also release the irritative chemicals such as Nitric Oxide, Substance P, etc., from the areas of nerve irritation.

Massage therapy enhances the transmission of these chemicals through the extracellular space, to the blood system, and their excretion through the kidneys. Massage therapy is essential for success of nerve blocks.

Thermography and CRPS

Hooshmand H, Hashmi M, Phillips EM. Infrared Thermal Imaging as A Tool in Pain Management – An 11 Year Study, Part II: Clinical Applications. Thermology International 11 / 3 (2001). Source: www.rsdrx.com and www.rsinfo.com

Infrared Thermal Imaging (ITI) can facilitate early diagnosis of Complex Regional Pain Syndrome (CRPS) (1), and can achieve a higher recovery rate among CRPS patients (2-5) by virtue of early diagnosis of the disease. CRPS cannot be accurately diagnosed by a single test. CRPS is a clinical diagnosis when the following four principles are met:

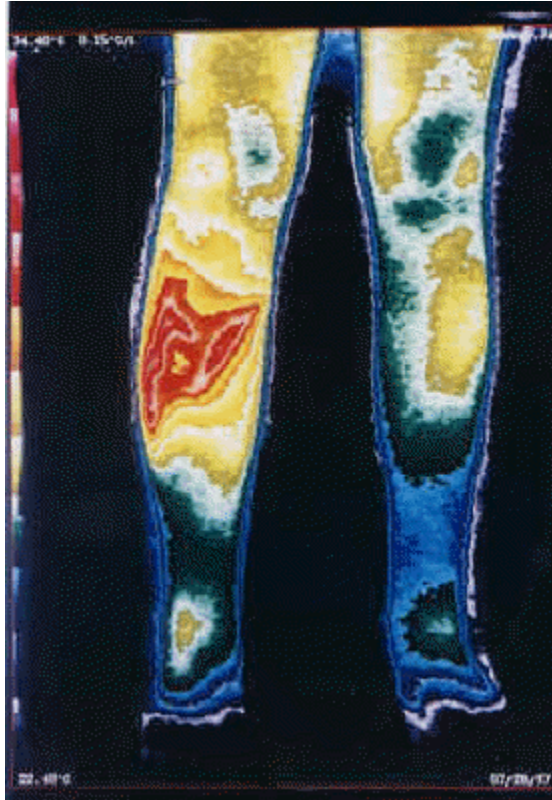1. Neuropathic, hyperpathic, or causalgic pain.
2. Vasomotor disturbance, flexor spasm, or tremor.
3. Inflammation at some point in the course of the disease.
4. Limbic system dysfunction in form of insomnia, agitation, depression, and poor memory (6,7).

Tests such as ITI are mainly helpful to obtain information regarding the nature and extent of the disease, and to guide the clinician in proper management of pain (3).

The ITI, like any other test, cannot be expected to show 100% diagnostic sensitivity. Even with the cold-water stress ITI testing (1,8,9), it is sensitive in 93 % of the patients, specific in 89 %, positive predictive value (PPV) of 90%, and negative predictive value (NPV) of 94% (1). Recently, Herrick et al (10), have found cold stress ITI is useful to diagnose patients suffering from fracture who are at risk for CRPS.

Lee and Weeks (9), in their meta-analysis of scintigraphic bone scan (SBS) showed this test to be positive in no more than 55% of CRPS patients (9,11). EMG and NCV (12,13), or CT and MRI cannot be expected to detect the microscopic perivascular nerve dysfunction in CRPS. Even if a coincidental disc bulging is seen on MRI, surgical procedure in the inflamed region is apt to severely aggravate the CRPS (14-16).

RSD-CRPS REFERENCE GUIDE



A previously undiagnosed right leg arteriovenous malformation (AVM) over 27mm deep, complicated by CRPS (RSD). ITI identified the deep lesion and spared the patient from the scheduled sympathectomy. Vascular surgery corrected the condition.

References

1. Gulevich SJ, Conwell TD, Lane J, Lockwood B, Schwettmann RS, Rosenberg N, et al: Stress infrared telethermography is useful in the diagnosis of complex regional pain syndrome, type I (formerly reflex sympathetic dystrophy) *Clin J Pain.* 1997; 13: 50-9.
2. Payne R: Neuropathic pain syndromes with special reference to causalgia and reflex sympathetic dystrophy. *Clin J Pain.* 1986; 2: 59-73.
3. Hooshmand H: *Chronic Pain: Reflex Sympathetic Dystrophy: Prevention and Management.* CRC Press, Boca Raton FL. 1993
4. Poplawski ZJ, Wiley AM, Murray JF: Post traumatic dystrophy of the extremities. *J Bone Joint Surg [Am].* 1983; 65:642-55.
5. Miller RD, Munger WL, Powell PE: Chronic pain and local anesthetic neural blockade. In Cousins JJ Bridenbaugh PE, eds. *Neural blockade in clinical anesthesia and management of pain.* Philadelphia: Lippincott. 1980; 616-36
6. Hooshmand H, Hashmi H: Complex regional pain syndrome (CRPS, RSDS) diagnosis and therapy. A review of 824 patients. *Pain Digest.* 1999; 9: 1-24.

RSD-CRPS REFERENCE GUIDE

7. Benarroch EE: The central autonomic network: functional organization, dysfunction, and perspective. *Mayo Clinic Proc.* 1993; 68: 988-1001.
8. Hobbins WB: Thermography and Pain. In *Biomedical Thermology*. New York. Alan R. Liss. 1982; 361-75.
9. Lee GW, Weeks PM: The role of bone scintigraphy in diagnosing reflex sympathetic dystrophy. *J Hand Surg [Am]*. 1995; 20:458-63.
10. Herrick A, el-Hadidy K, Marsh D, Jayson M: Abnormal thermoregulatory responses in patients with reflex sympathetic dystrophy syndrome. *J Rheumatol.* 1994; 21: 1319-24.
11. Demangeat JL, Constantinesco A, Brunot B, Foucher G, Farcot JM: Three phase bone scanning in reflex sympathetic dystrophy of the hand. *J Nucl Med.* 1988; 29:26-32.
12. Drummond PD, Skipworth S, Finch PM: alpha 1- adrenoceptors in normal and hyperalgesic human skin. *Clin Sci (Colch)*. 1996; 91: 73-7.
13. Dyck PJ: Limitations in predicting pathologic abnormality of nerves from the EMG examination. *Muscle Nerve.* 1990; 13:371-5.
14. Bar-shavi Z, Goldman R, Stabinsky. Y, Gottlieb P, Fridkin M, Teichberg VI et al: Enhancement of phagocytosis-a newly found activity of substance P residing in its N-terminal tetrapeptide sequence. *Biochem Biophys Res Commun.* 1980; 94:1445-51
15. Anbar M, Gratt BM: Role of nitric oxide in physiopathology of pain. *J of Pain and Symptom Mgmt.* 1997; 14: 225-54
16. Hooshmand H, Hashmi M, Phillips EM. Infrared Thermal Imaging as A Tool in Pain Management – An 11 Year Study, Part II: Clinical Applications. *Thermology International* 11 / 3 (2001).

RSD-CRPS and Social Security Disability Benefits

Reflex Sympathetic Dystrophy (RSD) and Social Security Disability Benefits

By: Attorney Richard J. Lawton Brockton, Massachusetts

Source: www.rsinfo.com

Reflex Sympathetic Dystrophy (RSD) is an incurable, rarely treatable and little-known disorder that attacks the limbs. Its main symptom is pain and is often unresponsive to various treatments which now exist.

Although the exact nature of RSD is poorly understood, the medical field acknowledges that RSD imparts a major disability by virtue of the chronicity of its pain. If as a victim of RSD, you have been disabled from engaging in substantial gainful employment due to pain, then you may be eligible for Social Security Disability Insurance benefits. Federal case law has held on numerous occasions that pain alone can be disabling in determining an individual's inability to engage in substantial, gainful employment.

In order to establish your disability to the Social Security Administration, it is vital that you or your attorney prepare credible documentation of convincing medical evidence sufficient to demonstrate that the RSD has imparted a tragic effect on your physical and mental abilities to do basic work activities.

By documenting the effects of RSD, one's physical and emotional function, is often possible to demonstrate that RSD can prevent one from maintaining adequate concentration, attention, production and pace to meet the regular attendance requirements of an entry level job to understand and follow complicated instructions and to deal with usual work-related stress.

The effects of RSD can vary from mild too chronically disabling and will deserve the time and attention of competent legal advice.

Social Security Ruling

The following information will be helpful to RSD/CRPS patients when filing for their Social Security Disability.

RSD-CRPS REFERENCE GUIDE

Titles II and XVI: Evaluating Cases Involving Reflex Sympathetic Dystrophy Syndrome/Complex Regional Pain Syndrome.

The link below is the file document [Social Security Ruling, SSR 03–2p], that was published in the Federal Register on October 20, 2003 (68 FR 59971) and became effective as of that date.

This ruling explains Social Security policies for developing and evaluating Title II and Title XVI claims for disability on the basis of Reflex Sympathetic Dystrophy Syndrome (RSDS), also frequently known as Complex Regional Pain Syndrome, Type I (CRPS).

These terms are synonymous and are used to describe a unique clinical syndrome that may develop following trauma. This syndrome is characterized by complaints of intense pain and typically includes signs of autonomic dysfunction.

Please go online to: <http://www.gpo.gov/fdsys/pkg/FR-2003-10-20/pdf/03-26332.pdf> to view the Social Security Ruling 03-2p document

*Another great resource to help you with your Social Security Disability claim is: www.Disabilitysecrets.com

Disabilitysecrets.com website provides tips, advice, explanations and answers to your Social Security Disability and RSD questions.

Please visit their website at: <http://www.disabilitysecrets.com/social-security-disability-rsd.html>

Let us know what you think

Please [give us feedback on this quick reference guide](#), so we can provide content that's truly useful and helpful. Thanks!

If you would like you more information regarding RSD-CRPS please visit our websites at www.rsdinfo.com and www.rsdrx.com or contact:

Eric Phillips

International RSD Foundation

Phone: 508-479-9888

e-mail: utopia33@prodigy.net



www.rsdinfo.com

Copyright ©2019 by: International RSD Foundation, Eric M. Phillips and H. Hooshmand, M.D.

All Rights Reserved. E-Mail: utopia33@prodigy.net